SONOGRAPHY PATTERNS DIAGNOSE DISEASE PROGRESSION

Ultrasound (US) Berlin Morphology Criteria Predict Metastatic Disease of the Sentinel Nodes (SN) in Melanoma Patients

[1]Christiane Voit, MD, PhD, [2]Alexander CJ Van Akkooi, MD, [3]Alfred Schoengen, MD, [1]Wolfram Sterry, MD, PhD, [4]Alexander MM Eggermont MD, PhD

[1]Department.of Dermatology of the Charité, Humboldt University, Berlin
[2] Department of Surgical Oncology, Erasmus University Medical Center – Daniel den Hoed Cancer Center, the Netherlands
[3]Dept. of Medical Oncology, Armed Forces Hospital, University of Ulm, Germany
[4]Cancer Institute Gustave Roussy, Villejuif/Paris-Sud, France

Corresponding author and reprint address:
Christiane Voit, MD, PhD
Dept. of Dermatology
Charité, University Medicine Berlin
Berlin, 10117
Germany
Email: christiane.voit@t-online.de
Tel: 0049 30 450 618007

Malignant melanoma is a malignant tumour that has experienced a large increase in incidence over the last decades (1-3). Due to campaigns to better detect and get aware of a malignant melanoma nowadays, many melanomas are detected at an early stage when they can be still excised. Those patients can be curably treated just by the excision and the concomitant wide excision regarding the national recommendations. Thus it is understood that the mortality rate is not increasing in parallel to the incidence. The reason why the mortality rate has only slightly increased is based on the predominant increase of thin melanomas with a good prognosis, which do not yet show distant dissemination (4).
In case a seed of tumour cells occurs, most melanomas primarily follow two different patterns of distribution (5).

Early clinical observation studies in cancer patients suggested that tumours spread in a methodical, stepwise fashion from the primary site, to the regional lymph nodes, and only then afterwards to distant locations (5). Based on these observations, the regional lymph nodes were believed to be mechanical barriers, at least temporarily preventing the widespread dissemination of tumour (**Barrier theory, linear spread**) (6). Thus early detection would lead to a better prognosis and with that to a better overall survival if metastases are detected early enough (7, 8). Following this theory it has been observed that also most melanomas follow an orderly progression and predominantly spread via the lymphatic ways to the lymph nodes. From the lymph node the disease may progress to distant organs by hematogenous dissemination or may stay restricted to lymph nodes (9).

Alternatively or in addition, a second way of dissemination is assumed. Distant metastases are said to develop from hematogeneously disseminated tumour cells that originate from the primary tumour - so right from the beginning and cannot be stopped if genetically planned **(“seed and soil” – theory, parallel spread**). Thus it is concluded that the number of positive lymph nodes is therefore simply a marker, but not a cause of distant metastases and treatment of lymph nodes would not affect long-term survival. This gene-based control of metastases implies a principal process of metastatic spread for solid tumours. The hypothesis "metastases do not metastasize" has a high plausibility. Following this hypothesis, reduction of lymph node dissection and above all its performance only in those cases where it is necessary for treatment decisions seems to be (bio)-logically consequent (9).

Following the first theory an elective lymph node dissection (ELND) was performed in former times in all melanoma patients with a certain tumour thickness, however, did not translate into a general survival benefit or only for subgroups, as could be proven (10-13). Those studies had shown that the ELND had some impact on prognosis only in special selected subgroups such as <60 years of age and an intermediate Breslow tumour thickness between 1 – 2 mm and was highly connected with side effects such as lymphedema (14, 15). Thus the elective lymph node dissection (ELND) is no longer recommended.

It was then quite a great step from an elective lymph node dissection to a lower grade surgical invention, which was introduced by the use of sentinel node biopsy (SLNB), which is now used world-wide following the primary diagnosis of a melanoma above 1mm tumour thickness (16).

This SLNB will be offered in experienced and qualified centers, which means an excision of the first lymph node within the drainage following an malignant tumor (16). The SLNB is based on a well working interaction between Dermatology, Nuclear Medicine and Pathology. So far it is seen as a selective staging procedure as compared to the former ELND, the elective, i.e. prophylactic lymph node dissection of lymph nodes of a basin without any knowledge of an involvement. The SLNB procedure is connected with only few side effects and morbidity. Furthermore, so far there are no studies proving any survival benefit for the SLNB staged patients and only 20% of these are normally positive in histopathology (4).

In case of verified lymph node metastases by SLNB without proof of further disseminated disease a completion lymph node dissection (cLND) will be the next step.

Researchers in Germany and the Netherlands have discovered ultrasound-based patterns that may accurately diagnose the presence and extent of lymph node involvement of a sentinel node in patients with melanoma. Thus ultrasound is seen as a tool to replace unnecessary SLNBs in some cases and in the same way predict patient survival.

The technique has the potential to spare patients unnecessary invasive procedures if combined with ultrasound-guided fine-needle aspiration cytology (FNAC) of lymph nodes. Thus for the first time ultrasound patterns have been prospectively

established that can be used as criteria for diagnosing disease progression and tumor burden (17).

The study is the product of an 11-year-long collaboration between Charité, the Daniel den Hoed Cancer Center at Erasmus University in Rotterdam, and the Department of Medical Oncology at the Armed Forces Hospital in Ulm, Germany. Thus far 1400 melanoma patients have been prospectively enrolled. Of these, all have already undergone sonography, conventional sentinel node surgical biopsy as the reference standard test, and the first 400 patients even an average of nearly 45 months of median follow-up (18). Patients with suspicious ultrasound findings always underwent ultrasound-guided fine needle aspiration cytology (FNAC).

The investigators tested several different ultrasound patterns and found that especially three of them, peripheral perfusion, loss of central echoes and balloon-shaped lymph nodes, provided consistent signs, respectively, of early- and late-stage metastatic disease. Researchers also found these signs could predict the amount of tumor burden before surgical biopsy in up to 90% of cases.

The balloon-shaped ultrasound pattern (BS), with or without central echoes, indicated a large number of cancer cells in the sentinel node in more than 80% of cases. The pattern appeared exclusively in cases of advanced metastasis.

Peripheral perfusion (PP), on the other hand, suggested an early sign of lymph node architecture disruption by angiogenesis. This pattern starts early, however, stays over time and can be seen still persisting in the advanced stages.

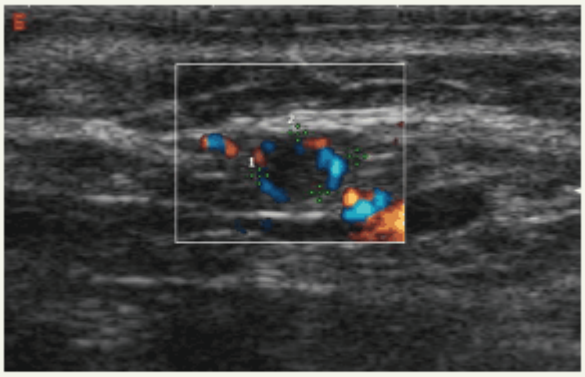

Normal (1) and diseased (2) lymph nodes featuring central echoes and central perfusion patterns in a patient with melanoma. The enhanced circular peripheral perfusion on power Doppler characterizes lymph node involvement. (Provided by C. Voit)

The “loss of central echoes” (LCE) is an ultrasound pattern “in between” these extremes reflecting a development from the early tumour involvement over the loss of central echoes (meaning a wandering of the brighter grey central echoes=hilum to

the rim) to the advanced metastases (which will be depicted as an echo-free balloon-shaped lymph node, see above).

These three ultrasound patterns could predict overall survival. Based on these findings, five-year survival rates of more than 90% were estimated for those patients who presented with neither pattern. Five-year survival rates for patients with peripheral perfusion (PP) and balloon-shaped (BS) patterns were 87% and 56%, respectively (17).

Surgical biopsy of the sentinel nodes (SLNB) remains the standard of care in cases of suspected metastatic spread from melanoma, but the practice is controversial. The invasive procedure could be unnecessary for about 80% of patients (cause only 20 % of sentinel nodes are normally involved in large SN populations), who might have to endure side effects such as chronic inflammation and seroma.

REFERENCES

1. Baade P, Meng X, Youlden D, et al.: Time trends and latitudinal differences in melanoma thickness distribution in Australia, 1990-2006. Int J Cancer 130:170-178, 2012

2. Simard EP, Ward EM, Siegel R, et al.: Cancers with increasing incidence trends in the United States: 1999 through 2008. CA Cancer J Clin, 2012

3. de VE, Steliarova-Foucher E, Spatz A, et al.: Skin cancer incidence and survival in European children and adolescents (1978-1997). Report from the Automated Childhood Cancer Information System project. Eur J Cancer 42:2170-2182, 2006

4. Balch CM, Gershenwald JE, Soong SJ, et al.: Final version of 2009 AJCC melanoma staging and classification. J Clin Oncol 27:6199-6206, 2009

5. van Akkooi AC, Voit CA, Verhoef C, et al.: New developments in sentinel node staging in melanoma: controversies and alternatives. Curr Opin Oncol 22:169-177, 2010

6. Pharis DB: Cutaneous melanoma: therapeutic lymph node and elective lymph node dissections, lymphatic mapping, and sentinel lymph node biopsy. Dermatol Ther 18:397-406, 2005

7. Lejeune FJ: The impact of surgery on the course of melanoma. Recent Results Cancer Res 160:151-157, 2002

8. Voit C, Mayer T, Kron M, et al.: Efficacy of ultrasound B-scan compared with physical examination in follow-up of melanoma patients. Cancer 91:2409-2416, 2001

9. Holzel D, Engel J, Lohrs U: [Elective lymph node dissections--still a standard in cancer surgery?]. Zentralbl Chir 133:582-589, 2008

10. Landry CS, McMasters KM, Scoggins CR: The evolution of the management of regional lymph nodes in melanoma. J Surg Oncol 96:316-321, 2007

11. Tsutsumida A, Furukawa H, Yamamoto Y, et al.: Sentinel node biopsy versus elective lymph node dissection in patients with cutaneous melanoma in a Japanese population. Int J Clin Oncol 12:245-249, 2007

12. Lens MB, Dawes M, Goodacre T, et al.: Elective lymph node dissection in patients with melanoma: systematic review and meta-analysis of randomized controlled trials. Arch Surg 137:458-461, 2002

13. Balch CM, Soong SJ, Bartolucci AA, et al.: Efficacy of an elective regional lymph node dissection of 1 to 4 mm thick melanomas for patients 60 years of age and younger. Ann Surg 224:255-263, 1996

14. Mariani G, Erba P, Manca G, et al.: Radioguided sentinel lymph node biopsy in patients with malignant cutaneous melanoma: the nuclear medicine contribution. J Surg Oncol 85:141-151, 2004

15. Miliotes G, Albertini J, Berman C, et al.: The tumor biology of melanoma nodal metastases. Am Surg 62:81-88, 1996

16. Morton DL, Wen DR, Wong JH, et al.: Technical details of intraoperative lymphatic mapping for early stage melanoma. Arch Surg 127:392-399, 1992

17. Voit C, van Akkooi AC, Schafer-Hesterberg G, et al.: Ultrasound morphology criteria predict metastatic disease of the sentinel nodes in patients with melanoma. J Clin Oncol 28:847-852, 2010

18. Voit CA, van Akkooi AC, Schafer-Hesterberg G, et al.: Rotterdam Criteria for sentinel node (SN) tumor burden and the accuracy of ultrasound (US)-guided fine-needle aspiration cytology (FNAC): can US-guided FNAC replace SN staging in patients with melanoma? J Clin Oncol 27:4994-5000, 2009